

## **ON A RADICULONEURITIS SYNDROME WITH HYPERALBUMINOSIS OF CEREBROSPINAL FLUID WITHOUT CELLULAR REACTION. REMARKS ON CLINICAL AND GRAPHICAL CHARACTER OF TENDON REFLEXES.**

MM. GEORGES GUILLAIN, J.-A. BARRÉ AND A. STROHL.

Translated by: Bassam Malo MD

We draw attention, in this note, on a clinical syndrome that we have observed in two patients, a syndrome characterized by motor disturbances, the abolition of tendon reflexes with conservation of the cutaneous reflexes, paresthesia with difficulty of objective light sensitivity, pain with the pressure of the muscle masses, little accentuated changes in electrical reactions of nerves and muscles, and the very notable hyperalbuminosis of the cerebrospinal fluid with absence of cytological reaction (albuminocytological dissociation). This syndrome seemed to us; depend on concomitant damage of spinal roots, nerves and muscles, presumably of infectious or toxic nature. It must be differentiated from simple radiculitis, pure polyneuritis and polymyositis. Experimental research by the graphic method on the speed of the reflex and their lost time, the modalities, muscle contractility, shows the reality of the participation of the entire peripheral motor unit in this syndrome. We insist particularly also on the hyperalbuminosis of the cerebrospinal fluid without cytological reaction, fact which, to our knowledge, has not been mentioned in similar cases.

Obs I. The soldier ..., of... Hussars, age twenty-five years, entered, on August 20 1916, the neurological center of the sixth army for motor disorders of the lower and upper limbs. The affection started around July 25th by tingling of the feet and weakness of the lower limbs that forced him to stop after 200 300 meters walk. Then tingling appeared the following days on upper limbs and the lower part of the face; muscle strength has weakened in the upper limbs.

These different symptoms were developed without apparent cause: the patient had no recent infectious disease, no angina, he had no symptoms of food poisoning, there was no great fatigue. We will add that in its pathological antecedents, we found no material fact, the patient denied any syphilitic infection and any alcoholic habit.

The first exam in August 25 has allowed us to observe the following symptoms

Muscular strength was diminished in a diffuse way in upper and lower extremities without, however, the presence of total paralysis; this decrease in muscle strength was especially accentuated at the limbs where we found great weakness of flexion and extension of the toes of the foot, and the hand fingers.

The trunk muscles were weak, and the patient being supine could not sit spontaneously without using support.

Walking was possible in a few steps with noted certain instability, and standing on one foot could not be maintained.

There was no trouble with the facial musculature.

The electrical examination of the upper limbs showed normal faradic excitability and good galvanic excitability for all muscles with strong shock; there was no polar reversal; It was noted a slight hypoexcitability of the extensor digitorum communis. The lower limbs faradic excitability was slightly decreased, the galvanic excitability was decreased for the trunk of the sciatic nerve, tibial nerve, the semitendinosus, the extensor digitorum; Sometimes the shock is slightly slowed; with the polar reversal for the external twin, but the degenerative reaction was very incomplete.

The patellar reflexes, Achilles, medio-plantar elicited by the hammer were abolished, same for antebrachial, radio and ulnar-pronator, and olecranon reflexes.

The plantar cutaneous reflex brings the flexion of the toes with remote contraction of the tensor fascia lata. Cremasteric and abdominal cutaneous reflexes are normal. There was no defense reflex either by pinching the neck of the foot, or by hyperflexion of the toes.

The neuromuscular excitability by the hammer was retained.

The patient complains of tingling in both feet to the top of the ankle and both hands to above the wrist. There are no distinctly appreciable objective sensitivity disorders, if not a slight hypoesthesia to tactile, thermal, and pain in feet and hands. The muscles of upper and lower limbs are painful to pressure.

The pupils, were equal, react to light and accommodation.

There are no sphincter disorders.

No fever, no respiratory or gastrointestinal disorder, pulse is normal.

Urine examined at the Laboratory of Bacteriology and Chemistry of the Army, contain no sugar, no albumin or indoxyl; chemical elements are in their normal proportions.

Lumbar puncture showed clear cerebrospinal fluid, normal pressure, hyperalbuminosis (2 gr. 5 of albumin per liter) without leukocyte reaction (2 to 4 cells per field).

The Wassermann reaction in the blood is negative.

Seeding pharynx and nasal mucus shows the absence of any diphtheria bacillus.

Treatment consists of absolute bed rest, frictions of upper and lower limbs, injection of strychnine, sodium salicylate and salol.

On August 27, tingling in the lower limbs was reduced.

On 2 September, some improvement in muscle strength is observed, and there is no more tingling in the feet; they persist in the hands; tendon reflexes remain abolished. A new lumbar puncture showed, as in the previous one, very strong hyperalbuminosis without appreciable leukocyte reaction.

On 19 September, motor disorders are much improved: the patient is able to walk for an hour, he can stand on one foot; paresthesia have completely disappeared to the lower limbs, they still persist, albeit attenuated, in the hands; tendon reflexes are clinically abolished, defense reflexes are zero, cutaneous reflexes normal; neuromuscular excitability seems normal to percussion by hammer in upper and lower limbs and face.

The patient, improving gradually, was sent to convalesce September 30.

Obs. II - Soldier D ... of ... regiment of infantry, thirty-five years of age, enters, September 5 1916, the Sixth Army Neurological Center for motor disorders of the lower limbs, which are shown in the following circumstances.

August 28, after nearly 15 km of walking, he feels abnormal fatigue, headache, and erratic pain in lower and upper limbs. He goes to sleep, but cannot sleep and shivers for part of the night. The next morning he walks with great difficulties to get a visit, he was exempted from service for four consecutive days. The condition has started by the paretic lower limbs and then reached the upper limbs. The fourth day he wants to go for five hours with his friends, but falls backwards with his bag and cannot get up. Carried to a first aid station, he is then evacuated to the Army Neurological Centre. These different symptoms are developed without apparent cause, he had no recent infectious disease, had no symptoms of food poisoning or other; it should be added that he is very positive about the fact that he has never contracted syphilis.

September 5, we have found the following symptoms.

The patient sketch with efforts small movements of flexion and extension of the toes, leg bending on the thigh and thigh on the pelvis. The same difficulty exists for the movements of the upper limbs where disorders predominate significantly in the periphery. The head is usually rotated left and the patient has difficulty to turn right; he can open and close the mouth, but slowly and incompletely.

Examination of electrical reactions shows a slight hyperexcitability of nerves and muscles with faradic current. With Galvanic current, excitability is slightly increased, especially for nerve of upper limb; there is no reaction of degeneration.

The patellar reflexes are very difficult to find because of muscle tone, they seem to exist. The ankle reflexes and medio-plantar are abolished. The state of upper extremities reflexes cannot be determined because of hypertonia and the impossibility of a complete muscular resolution. Plantar cutaneous reflexes show frank flexion of the toes; cutaneous abdominal and cremasteric reflexes are normal. There has been no defense reflex either by pinching the back of the foot, or by hyperflexion of the toes, but the patient perceives the sensations conditions caused by these excitations.

The neuromuscular excitability with percussion hammer is retained.

The patient complains of tingling of extremities, there is no disorder of objective sensitivity if not slight hypoesthesia to touch, pain and temperature in the feet and hands.

The muscles of the calf and forearm are painful to pressure.

The pupils were equally reactive to light and accommodation.

The patient urinates alone, he feels the need but do not perceives the flow of urine.

He has no fever, no Kernig sign, no nausea, no vomiting.

The urine examined at the Laboratory of Bacteriology and Chemistry of the Army contain no sugar, no albumin or indoxyl; chemical items are in their normal proportion.

It should be noted a cutaneous eruption appeared for three or four days, mainly localized to the upper chest and the lower abdominal area, characterized by eruption of erythematous patches, papules. Outside the areas we have reported, the eruptive items are scattered on the rest of the thorax and abdomen; no eruption was seen on upper or lower extremities.

Lumbar puncture showed clear cerebrospinal fluid, not apparently hypertensive, hyperalbuminosis (more than 0 gr. 85 albumin on Sicard spinoalbuminometer) without significant leukocyte reaction (3 to 4 cells per field).

The symptoms recorded at the first examination had a slight tendency towards improvement. As of September 20, we still noted, however, the weakness of the muscles of the peripheral limbs, the abolition of all tendon reflexes except left antebrachial reflex, the conservation of cutaneous reflexes, pain of muscular masses with pressure, paresthesia of the extremities with mild hypoesthesia. Small myoclonic jerks were also observed intermittently in the muscles of the calf and thigh. A new lumbar puncture has noted the same peculiarities of previous review: clear fluid, non-hypertensive, with a much accentuated hyperalbuminosis without leukocyte reaction (3 or 4 lymphocytes per field).

The patient was evacuated to the rear on 1 October.

Both observations we have just described are quite similar. In these two patients, there was no apparent detectable cause, they developed a clinical syndrome characterized, as we said at the beginning, by motor disorders reaching all muscles of the upper and lower limbs and predominant ends of these, the abolition of tendon reflexes with conservation All cutaneous reflexes, paresthesia with mild objective sensory disorders, pain with pressing the muscles, minimal changes of electrical reactions of nerves and muscles, quite special cerebrospinal fluid changes characterized by hyperalbuminosis without cytological reaction.

The accentuated hyperalbuminosis of the Cerebrospinal fluid without cellular reaction is a feature that seems important to report. This albuminocytological dissociation (Sicard and Foix) is observed more often in certain spinal cord compression in Pott's disease, in some cases of syphilis of the central nervous system, but no one has described, it seems, in pure radiculitis and polyneuritis.

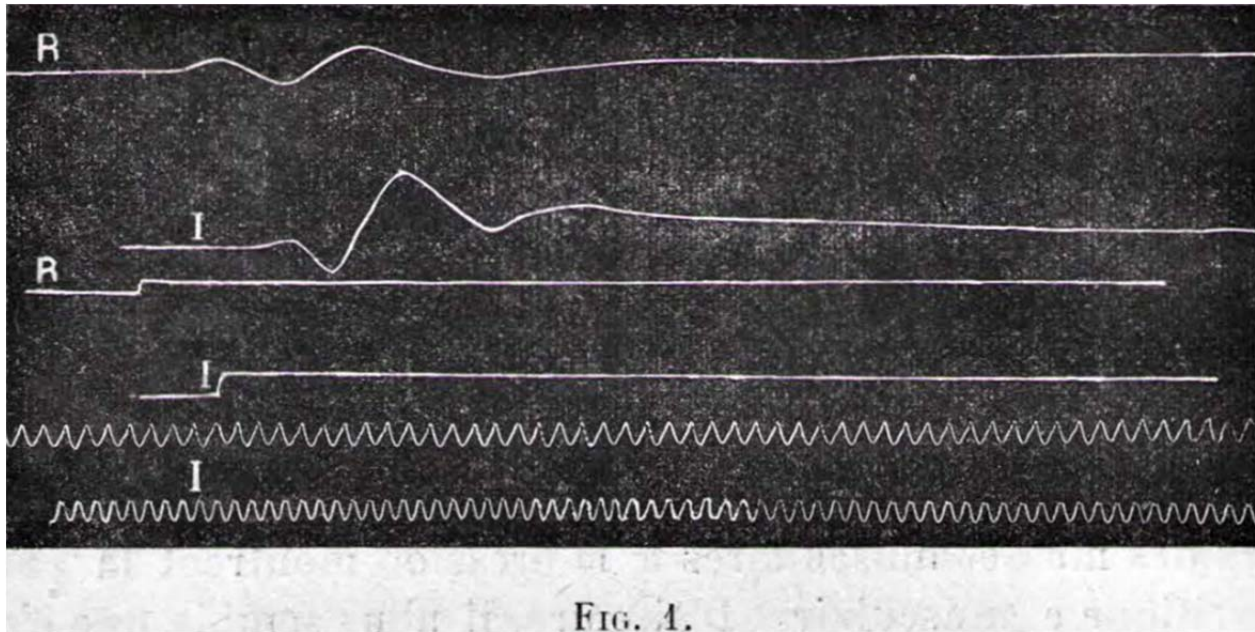
In our second patient, it is added on the paralytic element some muscular hypertonia that deserves to be highlighted. When the patient is at rest, the consistency of all the muscles is significantly higher than that of the muscles of a healthy individual in the same position. Passive movements retain all their normal amplitude. The limited voluntary movements, as we have said, are made with certain stiffness and slowness. The tendon reflexes are difficult to identify, muscles whose contraction was solicited was found to be constrained by the state of continuous antagonist contraction. Despite this set of characters that are found frequently in meningitis, the patient can sit by keeping the limbs almost completely extended, and the slight knee bend that may happens is overcome by an insignificant pressure. The legs raised and kept almost at right angles with the trunk flexed like those of a normal subject. The Kernig sign is therefore absent in our patient. This hypertonic state is therefore not related to meningitis, but with a special status in muscle contractility appearing depends on a peripheral nerve injury. *We have already stressed the fact that hypertonic states can happen in some peripheral neuritis and incomplete injuries of nerves, and specified on this occasion that contractures frequently observed in some facial paralysis are not an exception in peripheral nerves lesions, as is conventionally believed.*

All of these disorders in these two patients belong to simultaneous pathology of spinal roots, peripheral nerves, and muscles. The considerable hyperalbuminosis of cerebrospinal fluid demonstrates the meningeal involvement; the features of the paralytic diseases distally predominant and aching muscles to pressure show nervous and muscular participation. Moreover, it seems that in the neurology we isolate polyneuritis and polymyositis with big schema; in a very large number of cases of infectious or toxic polyneuritis, intramuscular nerve endings and muscle fibers themselves can be affected and can be very often a polyneuromyositis than pure polyneuritis.

In our first patient experimental research by graphic method allowed us to make some new characters in the study of reflexes and muscle contractility. The graphic method can provide important elements for the interpretation of symptoms and lesions.

In this patient, while the tendon reflexes appeared, on clinical examination, abolished throughout the course of the disease, the graphic registration of the swelling of the quadriceps and gastrocnemius muscles under the influence of an impact on their tendons or their muscular mass showed interesting features. Thus, from the beginning of the disease, the search for the knee jerk causes a contraction that clearly seen in Figure 1 after mechanical shaking. This contraction is significantly lower than what is

obtained in a healthy subject, occurs after a time lag about 0"056 and is not followed by a second wider and longer contraction which represents in the normal reflex curve the part of the actual muscle response "reflex". Hardly 0'152 after the start of the excitement, we notice a slight lifting of the curve showing the remains of the contraction reflex. The knee jerk thus remained almost entirely restricted to idio-muscle contraction until the cure of the disease. During this period the percussion of the mass of the quadriceps muscle caused a beautiful contraction occurring with a delay of 0"051, followed by a second contraction having all the characteristics of an original reflex jerk (Fig. 1) and occurring 0"150 after the start of the excitation. The muscle which responds weakly and partially to a mechanical excitation applied on its tendon and transmitted by propagation to the muscle fibers, shows, when hit directly, pretty normal double contraction. It seems to be the place of a mechanical hypoexcitability that makes it not excitable which can be carried by sudden deformation on the body of the same muscle.



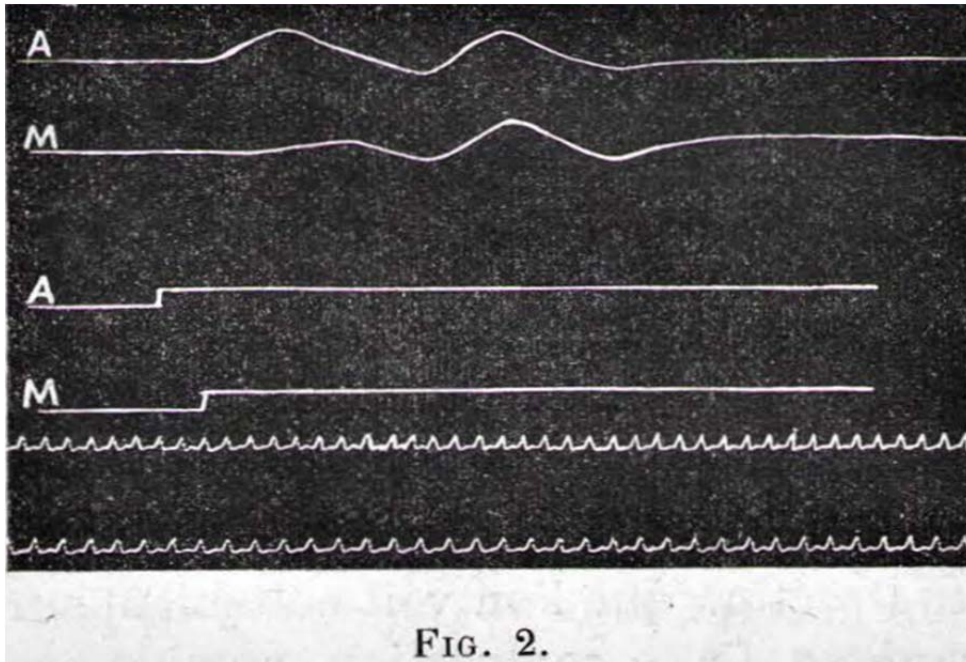
R, R, R, myographic curve of the quadriceps patellar reflex, with the signal of Desprez indicating the moment of percussion and time in 1/100 second.

I, I, I, the same marks for direct percussion of quadriceps muscle.

Registering 21 August 1916.

Note the almost total absence of contraction reflex following the percussion of the patellar tendon, whereas it clearly exists for the direct percussion of the muscle.

The ankle jerk shown, at the beginning, is also very modified and almost completely reduced to the mechanical shock. This (Fig. 2), very small amplitude, occurs after an extremely long time lost, about 0"110, and is not followed by any actual reflex contraction. But, contrary to what happened to the patellar reflex, these alterations were partially reversed, and by September 5 (Fig. 3), a new registration of the reflex could detect a wider, brighter, and faster muscle twitch (0'055), followed by a second shake recognizable as actual jerk reflex and occurs after a delay of 0"140. The neuromuscular twitch of the gastrocnemius followed a parallel evolution and gradual regain of a shape approximating normal.



**FIG. 2.**

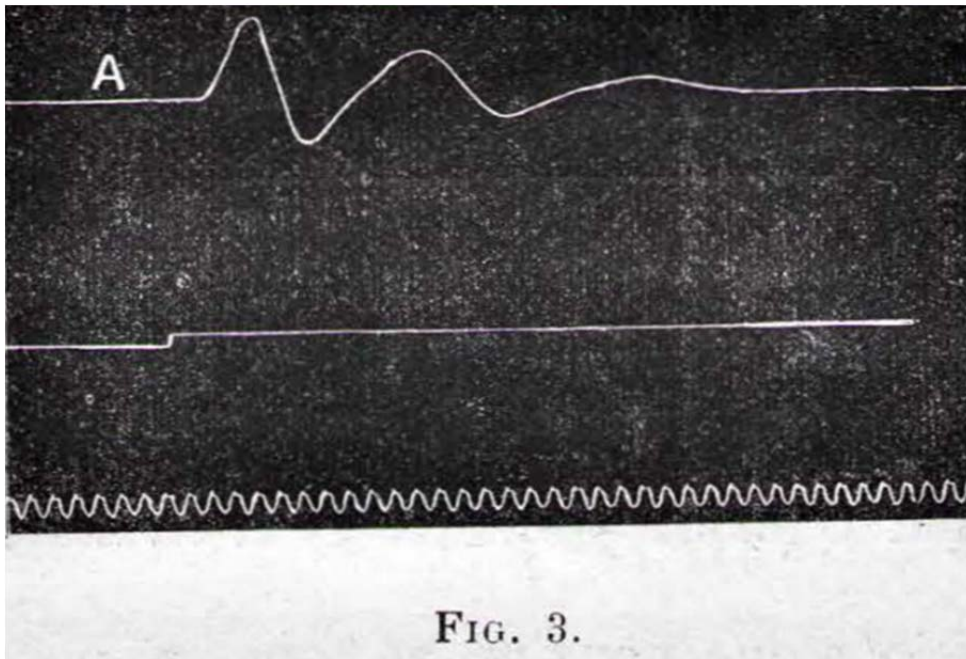
A, myographic curve of gastrocnemius (medial head) during Achilles reflex.

M, the same in the medio-plantar reflex.

Registering August 21, 1916.

The first elevation of the curve A is a mechanical shock, the second is a "Muscle" contraction.

The "reflex" which does not exist in the case of Achilles reflex is visible though very low on the curve of medio-plantar reflex.



**FIG. 3.**

A, myographic curve of gastrocnemius (lateral head) in the ankle reflexes.

Registering September 5, 1916.

The reflex is present with its three characteristics elevations. However, muscle contraction and especially the reflex contraction are lower than in a normal subject.

It is interesting to note that, during the beginning of the disease, the percussion of the tendon of Achilles and that of the gastrocnemius did not induce any muscle twitch, but at that time already, searching of the medio-Plantar reflex brought a second contraction with 0'144 delay and that it must look like a contraction reflex (fig. 2) of low intensity but clear.

In summary, while the simple clinical examination allows only seeing the abolition of tendon reflexes, detailed analysis of myographic curves, revealing on what elements of the reflex are altered, leads us to a series of newsworthy comments. First, the full disappearance of the reflex part from the myographic curve, or, where it exist, its morphological characters of extremely reduced amplitude, great slowness, and its considerable time lost, almost double the normal, show us the deep and predominant nerve conduction alteration or the central part of the reflex. But in addition, the muscle twitch seems also modified, reduced height, slowed and delayed in its appearance; it allows us to think that the muscular element was also affected by the process of intoxication. Finally, the comparison of the curves obtained after percussion of the patellar tendon and Achilles tendon shows different progression for these two reflexes. While the first was quickly abolished and did not show tendency to reappear until the moment where the patient has left the hospital, the second, although appearing abolished clinically, could be saved with characters gradually approaching normal. We insist on this important fact that the graphical method allows to have specific notions about the State of tendon reflexes much better than the exam with the percussion hammer.

The pathogenesis of radiculoneuritis syndrome observed in our patients could not be clarified. Infection or intoxications should no doubt be invoked, but we were unable to detect. The prognosis does not appear to be very serious, if we judge by the evolution of affection in our two patients, the first was almost healed and the second was developing improvement when he was evacuated from the army.